

# A New Measuring Index for Medical Rhinoplasty with HA Filler: A Review and Case-Series of TRI-HYAL Technology

Frederic Braccini<sup>1\*</sup>,  
Sarah Gougeon<sup>2</sup> and  
Solène Trevisan<sup>2</sup>

- 1 Facial Plastic Surgery, Facial Plastic Surgery Unit, "L'Artistique" Medical Healthcare Center 27 Boulevard Dubouchage, 06000 Nice, France
- 2 Newtone Technologies, Lyon, France

\*Corresponding author: Frederic Braccini

✉ frederic.braccini@gmail.com

Tel: + 33 (0)4 93 91 91 92

"L'Artistique" Medical Healthcare Center 27 Boulevard Dubouchage, 06000 Nice, France.

**Citation:** Braccini F, Gougeon S, Trevisan S (2021) A New Measuring Index for Medical Rhinoplasty with HA Filler: A Review and Case-Series of TRI-HYAL Technology. J Aesthet Reconstr Surg Vol.7 No.2:18

## Abstract

**Context:** Rhinoplasty is one of the most common aesthetic procedures performed by plastic surgeons. Over the last decades, medical rhinoplasty, or non-surgical rhinoplasty have become a common complementary or alternative of aesthetic surgery especially in Asian population. Hyaluronic acid fillers have become the mainstay treatment for medical rhinoplasty. The major advantages of HA are its malleability, the low potential for immunogenicity and the possible reversibility.

**Objective:** The aim of this trial was to assess the effect of dermal filler in the reduction of nose tortuosity. In addition, this didactic article also aimed to share tips, tricks and guidelines based on a large experience acquired during almost 15 years of medical rhinoplasty.

**Methods:** Medical records of 982 patients who had the non-surgical approach for aesthetic disorders of the nasal pyramid at the investigator's clinic (Nice, France) between 2006 and 2019 were examined retrospectively. Among them, 50 cases treated with the Art filler Universal from FILLMED Laboratories, France were randomly selected. The ratio between the length of the curve and the length of the line linking the two end points is defined as the "tortuosity" or "Braccini Index". The measuring technique (Newtone® Technologies) was performed on photos.

**Results:** 86% (n=43) of the subjects demonstrated a significant decrease of the "Braccini Index" from  $1.007 \pm 0.004$  at T0 to  $1.003 \pm 0.002$  at T1 ( $p < 0.05$ ). This statistically significant decrease of the Braccini Index reflects a decrease of the nose bridge.

**Conclusion:** MR represents an interesting first line treatment in patients that are not willing to have surgery, who have contra-indications for the surgery or for patients who do not seek permanent and radical solution. The selection of dermal filler with the relevant rheological properties is a key factor in achieving a natural-looking long-lasting desired aesthetic outcome. ART FILLER® Universal (Laboratoires FILLMED, France) showed a great safety and a significant efficacy to decrease the tortuosity of the nose bridge.

**Keywords:** Dermal Fillers; Hyaluronic Acid; Medical Rhinoplasty; Newtone® Technology; Nose Injection

**Received:** January 21, 2020; **Accepted:** February 09, 2021; **Published:** February 16, 2021

## Introduction

Rhinoplasty is one of the most common aesthetic procedures performed by plastic surgeons. Along with blepharoplasty, they are two of the most common cosmetic surgical procedures with

220,000 rhinoplasties performed yearly in the US, according to the American Society of Plastic Surgeons. This increase of cosmetic surgery is especially visible among Asians due to Western influence and globalization [1].

Rhinoplasty is considered to be one of the most challenging procedures in facial surgery and can simultaneously improve breathing and achieve a more balanced appearance. Rhinoplasty is a complex procedure for which indications should be carefully determined. Although the surgical procedure is relatively standardized, 5 to 15% of patients undergo revision rhinoplasty following a primary surgical nose job [2].

Over the last decades, medical rhinoplasty (MR), or non-surgical rhinoplasty, has become a common complementary or alternative of aesthetic surgery. Medical and surgical rhinoplasties should not be considered as competing, the latter remaining the gold standard in terms of long-term efficacy. However, MR represents an interesting first line treatment in selected cases, especially in patients that are not willing to have surgery, have contraindications or as a complement to surgical procedure. Primary MR is indicated for nose sculpting, camouflage, augmentation or refinement. While secondary MR is indicated after surgery to correct imperfections, to avoid adhesences before healing and for the treatment of nasal valve dysfunction. Compared to surgery, MR is easier, faster, safer and more cost-effective which makes the procedure more accessible to clinicians and patients. Since no tissue is damaged during MR, the recovery is faster with a limited downtime and the procedure leaves patients scar-free. However, injections of fillers in particular in nose should follow strict technical rules and use safe and controlled products to avoid side effects especially embolization, which remains very rare. Different type of fillers and procedures are available. Historically, these fillers consisted of autologous fat, silicone, poly-tetrafluoroethylene, poly-methylmethacralate, calcium hydroxyapatite, polylactic acid, or hydrogel [3]. However, over the last two decades, hyaluronic acid (HA) fillers have become the mainstay treatment for MR. The major advantages of HA are its malleability and the low potential for immunogenicity. Importantly, full reversibility of the treatment is possible with the administration of hyaluronidase. Compared to

other areas of the face, nose has the advantages to show superior durability. Results obtained during a session will be visible for one to three years depending on the patient.

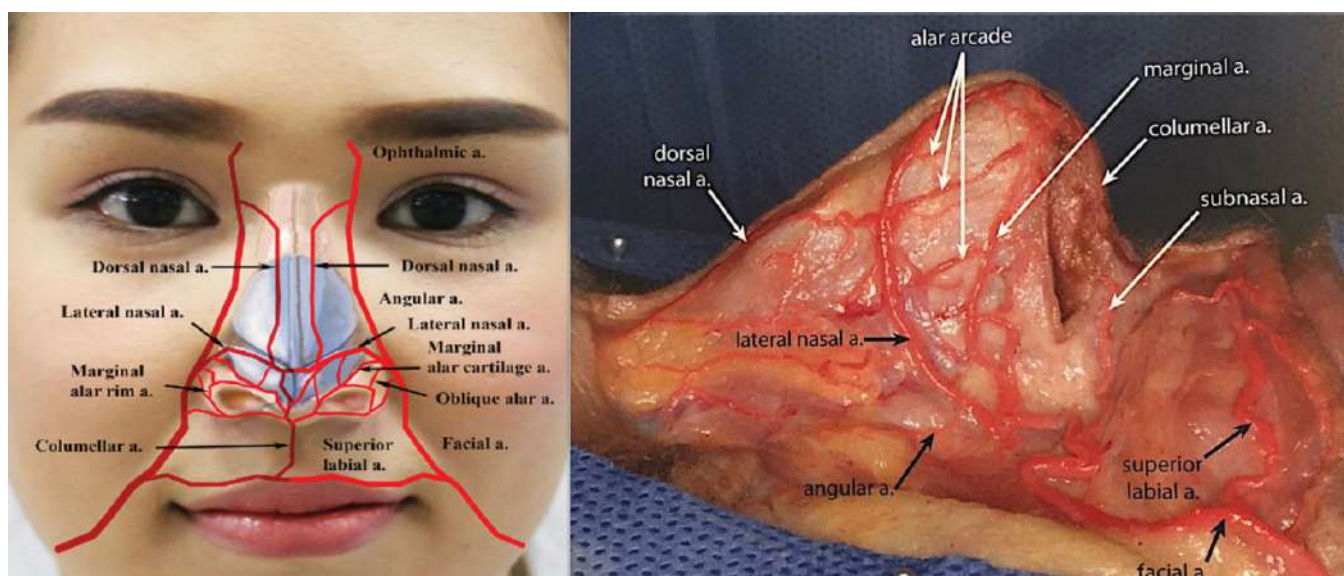
Although the safety profile of hyaluronic acid fillers is favourable, adverse reactions can occur. Most of these are mild and transient. Complications might be classified as early or late reactions. Early adverse reactions to HA fillers include vascular infarction; inflammatory reactions; injection-related events such as pain, ecchymosis, erythema, bruising or bleeding; and inappropriate placement of filler material. Among late reactions are nodules, granulomas, and skin discoloration [4]. Vascular complications are infrequent but can lead to serious side effects, such as tissue necrosis and vision loss.

Anatomical basis are essential to determine the location of the treatment and understand the potential risks related to the injections. The nose is an empty triangular pyramid with an osteochondral structure, where the base is the nostrils and the top corresponds to the nasal root. Over this osteochondral frame lies a perichondrial and periosteal envelope, a muscular layer, and the skin.

Hyaluronic acid injections are performed deeply, in contact with the cartilage or bone structures. That is to say the knowledge of nasal structure in both soft tissue and nasal frame is crucial before starting a medical rhinoplasty treatment with filler products.

The nose is highly vascularized, with small-sized blood vessels except for the internal canthus region (**Figure 1**). This vascularization depends on arterial branches of both internal and external carotid arteries, respectively the ophthalmic and facial arteries. Veins drain mostly to the angular vein but to the facial vein as well. Despite this abundant vascularization there are few risks of hematoma, whereas the major risk stands in vascular embolization, in particular in nasal ala and glabella.

Tip injections are not harmful if respecting the habitual technical



**Figure 1** Schematic and anatomical nasal vascularization.

precautions. The motor branches come from the facial nerve, and sensitive branches from the trigeminal nerve through infra-orbital and external nasal nerves. Injury of a nerve branch during procedure usually has no significant implications.

### HA rheological characteristics for nose injection

The physical properties of the filler, the concentrations, injection forces, particle sizes, difference in the manufacturing processes, rheological properties as well as the layer to be injected in, should be considered by the physician before performing filler injection [5]. Fillers should have enough lift capacity and longevity and they should not migrate a few months after the injection.

When filler is injected, it is subjected to shear stress and vertical compression/stretching forces, both of which cause the filler to deform. Among the rheological properties, viscoelasticity, cohesivity and viscosity are the three most important to determine filler performance [6].

Viscoelasticity and shear deformation are defined by  $G^*$  (measures overall viscoelastic properties or "hardness"),  $G'$  (measures elastic properties),  $G''$  (measures viscous properties), and  $\tan \delta$  (measures the ratio between viscous and elastic properties) [7].  $G'$ , the storage/elastic modulus, measures the elastic behavior of a gel or how much it can recover its shape after shear deformation.  $\tan \delta$  refers to the elasticity of a material. It determines whether the material is mainly elastic ( $\tan \delta < 1$ ), exhibiting a gel-like behavior, or whether it is mainly viscous ( $\tan \delta > 1$ ), behaving more like a viscous liquid. In cross-linked HA fillers,  $\tan \delta$  is usually low (ranging from 0.05 to 0.80), meaning that the elastic behavior under low shear stress is dominant over the viscous (i.e., liquid) behavior. For any facial filler to be effective, it needs to be viscoelastic in order to deform enough to be injected under high strain and to be initially molded but elastic enough to provide a durable correction by resisting shear deformation forces once implanted into soft tissue.

Cohesivity is described as the internal adhesion forces holding together individual cross-linked HA units and corresponds to the resistance to compression or stretching forces in a vertical plane once the product is injected [6,7]. Filler with high cohesivity can resist vertical compression and maintain the initial shape of the gel deposit. Lack of cohesivity between the gel particles also increases the chance of particles separating from the deposit, potentially causing migration of the filler.

Viscosity corresponds to a filler's resistance to flow when shear stress is applied. It has a low relevance for clinical performance but a high relevance for ease-of-injection. An ideal HA filler is one with low extrusion force, allowing for ease and precise dosing during injection. Too soft filler can spread relatively, making it difficult to shape the target area.

For nasal projection, where the main force is compression because of skin and tight muscle tension over the prominent bony structures, the filler of choice would have high cohesivity and high  $G'$  [6]. This type of filler will minimize lateral spreading, ensure good projection capacity, good malleability and keep a sharp vertical projection over time. A filler in this area is not submitted to intense shear stress.

ART FILLER® Universal is a medium range versatile HA filler with a good cohesivity, easy to mold and sculpt which is balanced between smoothing, volumizing and sculpting effect. It contains 25mg/mL of hyaluronic acid and 0.3% of Lidocaine. Its elasticity and cohesivity make it, from our point of view, a product perfectly suited to adapt to the constraints and requirements of filling the nose. The long-term efficacy and safety of this filler is evaluated through a 18 month follow up study [8]. These characteristics guarantee its performance and tolerance in this special zone.

Only a few prospective studies focused on the efficacy, safety, and longevity of HA fillers to support their utility as a non-surgical alternative to rhinoplasty. The aim of this trial was to present a case series of patients treated with HA and review the advantages and limitations of MR.

## Materials and Methods

### Experience in medical rhinoplasty

Medical records of 982 patients who had the non-surgical approach for aesthetic disorders of the nasal pyramid at the investigator's clinic (Nice, France) between 2006 and 2019 were examined retrospectively. 824 women and 158 men were included, with different indications: 392 primary medical rhinoplasties and 590 cases of secondary medical rhinoplasty corrections after one or several non-successful surgeries. Written informed consent was obtained from all patients. Photos were taken before (T1) and immediately after (T2) and also one month after the injection (T3). Fillers were used alone in 912 cases, botulinum toxin alone in 12 cases, and both products were used together in 58 cases. Botulinum toxin was always an A-type toxin (Bocouture, Laboratoires MERZ, Germany).

For the main interest of this study, in this global group of medical rhinoplasty performed only with filler, we have randomly selected 50 cases treated since 2016 with the same filler, Art filler Universal from FILLMED Laboratories, France. The measuring technique (Newtone® Technologies) was performed only on the photos of these randomized samples of 50 patients.

### Injection technique

After full discussion with the patient about the desired and expected results and the whole procedure of HA injection to correct nasal deformities, with clarifications of potential complications, consent should be signed. An over correction is to be avoided on the first procedure, so a follow up visit to be scheduled after two weeks. If necessary, a second injection can be done after 1 month. These can remain stable for 18-24 months.

Ideally, the intervention should be made after the application of an anesthetic cream overall the treated surface. The nasal tip is the most sensitive part. Indeed, the nasal cutaneous tension, particularly in the tip area, is so important that if too many injections are made, the product tends to extrude. There are several treatment procedures a follow:

### Filling the hump and working on the dorsum area

A 25 G canula is obliquely introduced (45°) until reaching the

bone, being held by the dominant hand (**Figure 2**). It is vital to press on the side walls of the nasal bones with the thumb and the index of the other hand. This prevents any diffusion of the product laterally, which can go undesirably, up to the level of the inner canthus and the lacrimal ducts. Sometimes, filling the nasofrontal angle by a lateral access is necessary to get a satisfactory result. The injection of the nasofrontal angle gives an impression of shortening the nose in profile. At the end of the procedure, the nose was manually modelled in order to improve the product distribution. In case of bolus injection with needle (**Figure 3**), it is recommended to aspirate before injecting the filler.

### Tip definition

Indications for tip correction can be lifting in case of parrot beak-shaped nose (drooping tip) or redefining the contour like in box nose shape (**Figure 4**). In order to reduce the risk of adverse event, especially tissue necrosis, multiple injection points should be avoided, as well as a controlled injection pressure and a slow and progressive injection. Clinically, the tip shouldn't whiten durably after fillers injection. In our experience, we have never observed cutaneous necrosis. For a cutaneous necrosis to appear, the substitutions networks have to be "overwhelmed". Embolization risks are therefore more important with low reticulation products (long possible migration to the distal capillaries). This is one of the reasons why high concentration and high reticulation fillers are recommended for the nasal area.

### Treatment of columellar region and opening of the naso-labial angle

The filler is injected deeply, in contact with the nasal spine, in order to open the angle. Then, the columellar lines can be balanced more superficially. A 25 G micro cannula can be used (**Figure 5**). This procedure is recommended only if no botulinum toxin injection is planned in the same time.

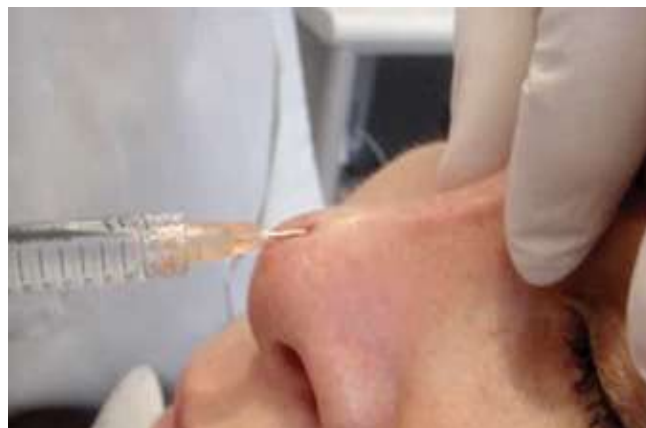In some case, we can perform all the procedure with a unique entry point at the tip (**Figure 6**). If the cannula is the reference and the safest recommendation, the use of needle can also be done with retracing technique and retro aspiration before bolus injections.

### Evaluation Methods

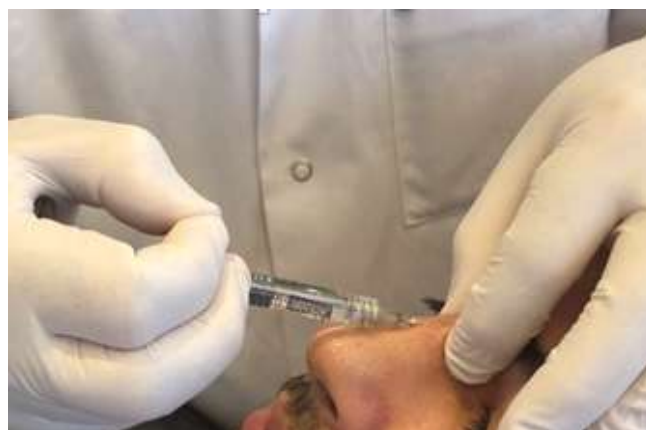The primary objective of this clinical study was to investigate specifically the efficacy of ART FILLER® Universal (Laboratoires FILLMED, France) on the nose bridge after injection in a panel of 50 subjects. The primary endpoint was to follow the evolution of nose bridge parameters over time by Newton® Technologies.

Standardized pictures were taken at T0 (before injection), T1 (30 min to 1 month after injection). Images were then analyzed by Newton® Technologies. This technology could measure very precise evolution of the selected lines over time. This analysis is performed on images which ensure a robust analysis.

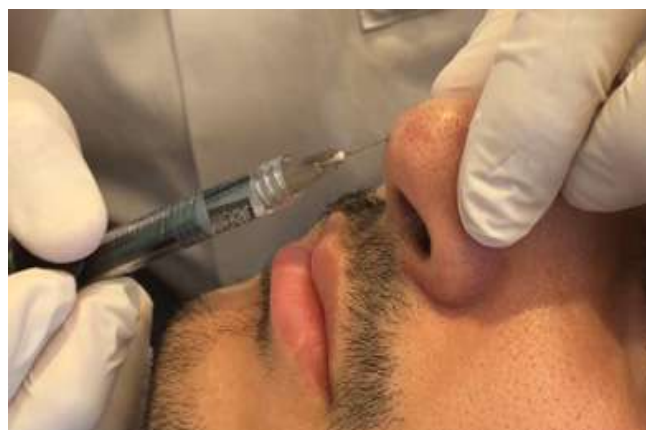Morphological points are manually defined along the nose bridge for each subject at baseline and all other time points blindly by the Newton® technicians. The number of points can be adapted depending on the morphology of the subject. The curve linking



**Figure 2** Dorsal injection with cannula 25 G.



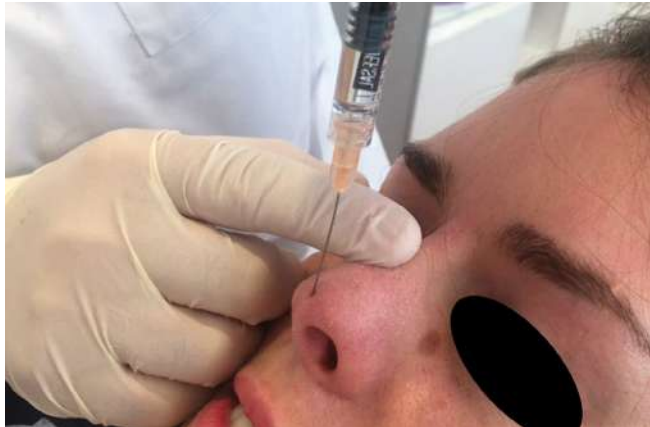**Figure 3** Dorsal injection with needle 27 G.



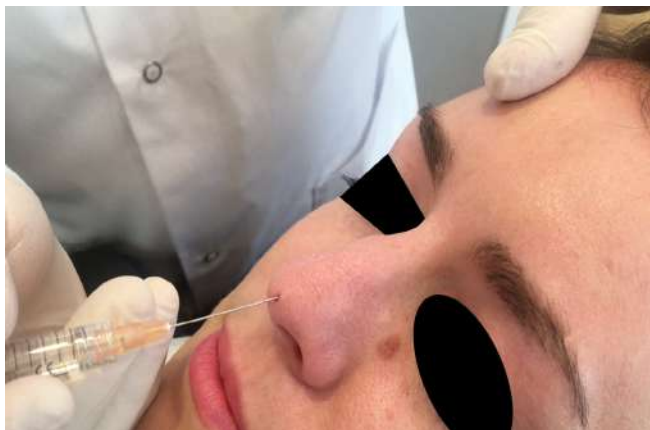**Figure 4** Tip injection with needle 27 G.

all defined points is automatically computed by the algorithm and it is precisely following the nose bridge. The following images (**Figure 7**) illustrate the defined morphological points and the defined line:

The ratio between the length of the curve and the length of the



**Figure 5** Collumelar and naso-labial injection with canula 25 G.



**Figure 6** Canula injection with unique entry point at the tip. In order to fill the full nose area with a 25G canula.

line linking the two end points is defined as the “tortuosity” or “Braccini Index”. A decrease of the “Braccini Index” results in an increase of the nose bridge linearity. Wilcoxon test was performed using XLSTAT 2019 software to compare values of each time point to those of T0.

The secondary endpoint was the tolerance and safety of this method. All of the expected and non-expected side effects were recorded in the medical profile of the patients.

## Results

### Demographic data

The study population consist on 50 patients (39 women and 11 men) followed during 6 months from June to December 2019 at “L’Artistique” Medical Healthcare Center (Nice, France).

The mean age was 32.55 years old.

### Image analysis by Newton® technology

The values of nose bridge parameters are calculated for all volunteers on the nose over time. The following **Table 1** presents the mean values observed in the study. The values

in bold correspond to p-value less than 0.05 indicates that the comparison is significant.

### Safety and tolerance

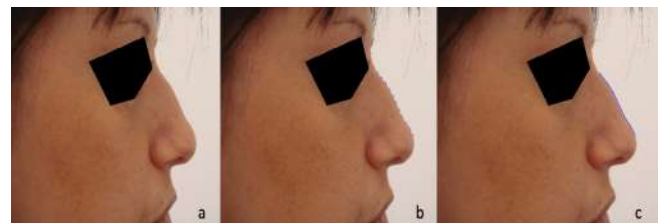
Neither surgical complications, nor serious adverse events have been reported

### Before-After qualitative evaluation by standard photography

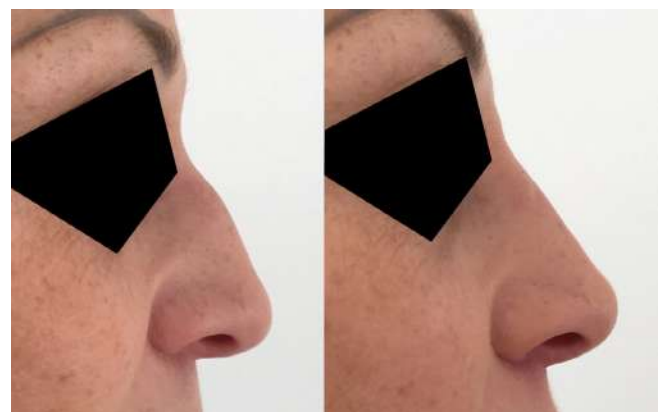The standard photography was performed in the same place and light, with the same device before (T0) and immediately after the injection at 30 min (T1) and 1 month (T3) after the injection (**Figures 8-11**). Among the subjects, 86% (n=43) subjects demonstrated a significant decrease of the “Braccini Index” from  $1.007 \pm 0.004$  at T0 to  $1.003 \pm 0.002$  at T1 ( $p < 0.05$ ). This statistically significant decrease of the Braccini Index shows a decrease of the nose bridge.

**Table 1** Statistical results of tortuosity analysis (Braccini Index).

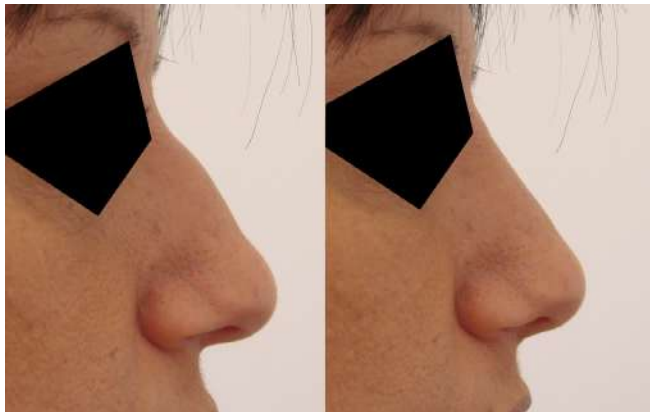Variables	Tortuosity parameter
T0	$1.007 \pm 0.004$
T1	$1.003 \pm 0.002$
T1-T0	$-0.004 \pm 0.004$
P value	<b>S (&lt; 0.001)</b>
Statistical significance	Signed Wilcoxon



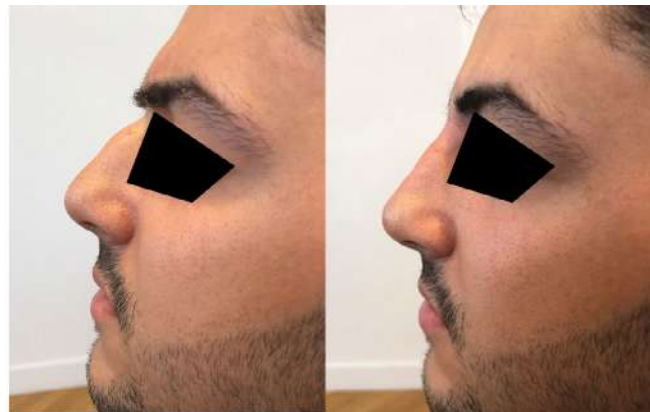
**Figure 7** Original image, Original image with defined morphological points and Original image with defined line.



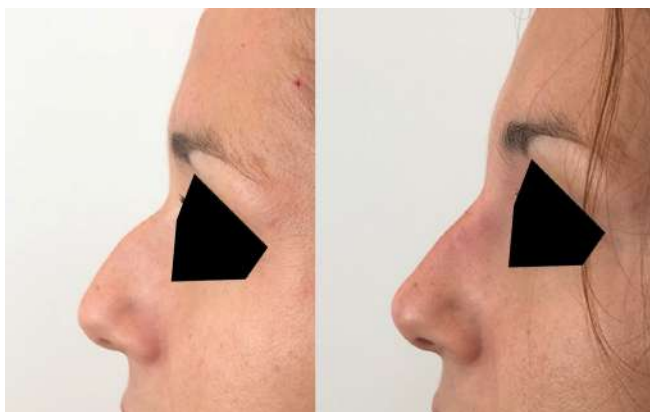
**Figure 8** Before and 1 month after the injection of Art Filler Universal (Laboratoires FILLMED, France).



**Figure 9** Before and 1 month after the injection of Art Filler Universal (Laboratoires FILLMED, France).



**Figure 10** Before and 1 month after the injection of Art Filler Universal (Laboratoires FILLMED, France).



**Figure 11** Before and 1 month after the injection of Art Filler Universal (Laboratoires FILLMED, France).

world especially in Asia where rhinoplasties are the second most common cosmetic surgical procedures after blepharoplasty. More than half of the world's population resides in Asia and there has been a tremendous growth of cosmetic surgery among Asians largely due to Western influence and the strength of native economies. In some countries, like in Iran, nose job is not just a cosmetic surgery to correct aesthetic defects; it has become a part of a fashion trend. Many consider a nose job a luxury to show their financial power and make girls marriageable; others wish to boost their self-confidence [9]. However, it has been shown that, more than only esthetic, rhinoplasty results in a significant improvement in the persons' quality of life [10]. More recently young men also are pursuing rhinoplasty and some of them for several times. An Iranian epidemiologic trial showed that the trend to undergo cosmetic surgery was more prevalent in educational below bachelor degree, married subjects and women population of 30-45 years age group [11]. Among the socio-psychological factors, self-improvement, finding a better job opportunity, rivalry, media, health status as well as depression were the most persuasive factors to encourage people to undergo cosmetic surgery too. Importantly, the cost risk was not important in decision making to undergo cosmetic surgery

Among the different types of fillers, HA has become the mainstay treatment for MR. Treatment is carried out using varying viscosities of hyaluronic acid, a naturally occurring substance in the human body which creates volume in the dermis. The absence of high mechanical stresses (facial dynamic rather poor in this area) associated with stability in the supports of the nasal pyramid (cartilages and bones) induces on the injections, a precision and a durability superior to other areas of the face. HA is indicated in both aesthetic and medical indications such as nasal septum deviation. The procedure can be performed safely in dermatology outpatient clinics. The major advantages of HA are its malleability, its low potential of immunogenicity, its durability and its reversibility with the availability of an effective rescue procedure. In addition, after injection no downtime is necessary. Although HA fillers are completely absorbed over time, the clinical results don't completely disappear. Therefore, during follow-up the volume injected may be reduced and sessions can be spaced over the time, which explains the durability of the effect. The high viscosity coupled with high cohesivity make Art Filler Universal (Laboratoires FILLMED, France) an ideal agent for nose correction. It is a versatile product, with a very good balance between smoothing, volumizing and sculpting potential. Thanks to a moderate  $G'$ , it has a good correcting power. Associated with its good cohesivity and a high  $TAN \delta$ , it is an easy-to-shape gel, with a good tissue integration, that is adapted to the most of the face zones. As Gavard-Molliard et al. showed, an appropriate viscosity and cohesivity of the HA filler provide the capacity to be easily moldable after injection during massage, allowing the product to be adequately placed, distributed and homogenized within the tissues, without fragmentation of the gel [12].

To increase HA efficacy, other therapies can be associated to MR such as mesotherapy or botulinum toxin [13]. Despite its large indication, MR is not indicated to correct volume excess and in case of important anomalies where the surgery is recommended.

## Discussion

Rhinoplasty is one of the most common cosmetic procedures performed by plastic surgeons. However, nonsurgical nose jobs with a dermal filler are becoming increasingly popular in the

A case series of 50 subjects showed that a unique course of injection of ART FILLER® Universal (Laboratoires FILLMED, France) significantly improved the nose by decreasing the tortuosity parameter. In addition, this effect was rapid and safe since no adverse event was reported.

The ideal nose profile should not be a straight line but a discrete curve. The ideal nasal tip should have specific characteristics, which are not always gathered such as:

- nasal tip autonomisation, when its projection is lightly longer than the dorsum one,
- visualisation of cartilage shapes and relief, in cases with thin skin
- “lobulo-columellar double break” that individualizes the apical lobule segment and the columella

Assessment of rhinoplasty outcome is poorly described in the literature and often limited to subjective assessment through self-assessment questionnaire [14]. Only few articles aimed to quantitatively assess rhinoplasty outcomes [15-17]. Among them, Grymer used acoustic rhinometry to evaluate the internal dimensions of the nasal cavity [15]. This method is based on acoustic reflections and aimed to evaluate, mainly, the anatomical modification after nasal surgery. In 2008, Hormozi et al. measured 7 rhinometric parameters before and after surgical rhinoplasties [17]. The authors concluded that rhinometry can be used as a guide for preoperative planning and as an instrument for assessing operation outcome and for comparing different procedures that play a role in any given aspect. Huempfer-Hierl et al. assessed the aesthetic and respiratory outcome of rhinoplasty in cleft patients who underwent nasal surgery [16]. To assess nasal respiration, active anterior rhinomanometry, rhinoresistometry, and acoustic rhinometry were performed. For analyzing the changes in aesthetic parameters, photographs from 3 directions were taken. A multitude of angles and relations of lines were created out of 54 anthropometric points. Regarding aesthetic outcome, a significant improvement in many parameters was observed. Regarding functional respiratory outcome, a significant increase in nasal volume was observed but no change in nasal airflow and hydraulic diameter could be found. The main difficulty in such trial is to interpret the variability of response of this multitude of parameters and identify the most relevant ones. In comparison, Braccini index has the advantage to combine different information in a unique quantitative index.

These studies were performed in the context of surgical rhinoplasty, the relevance and the accuracy of these rhinometric parameters in the context of medical rhinoplasty remain to be demonstrated. To our knowledge the Braccini index is the first quantitative parameter to assess the efficacy of medical rhinoplasties.

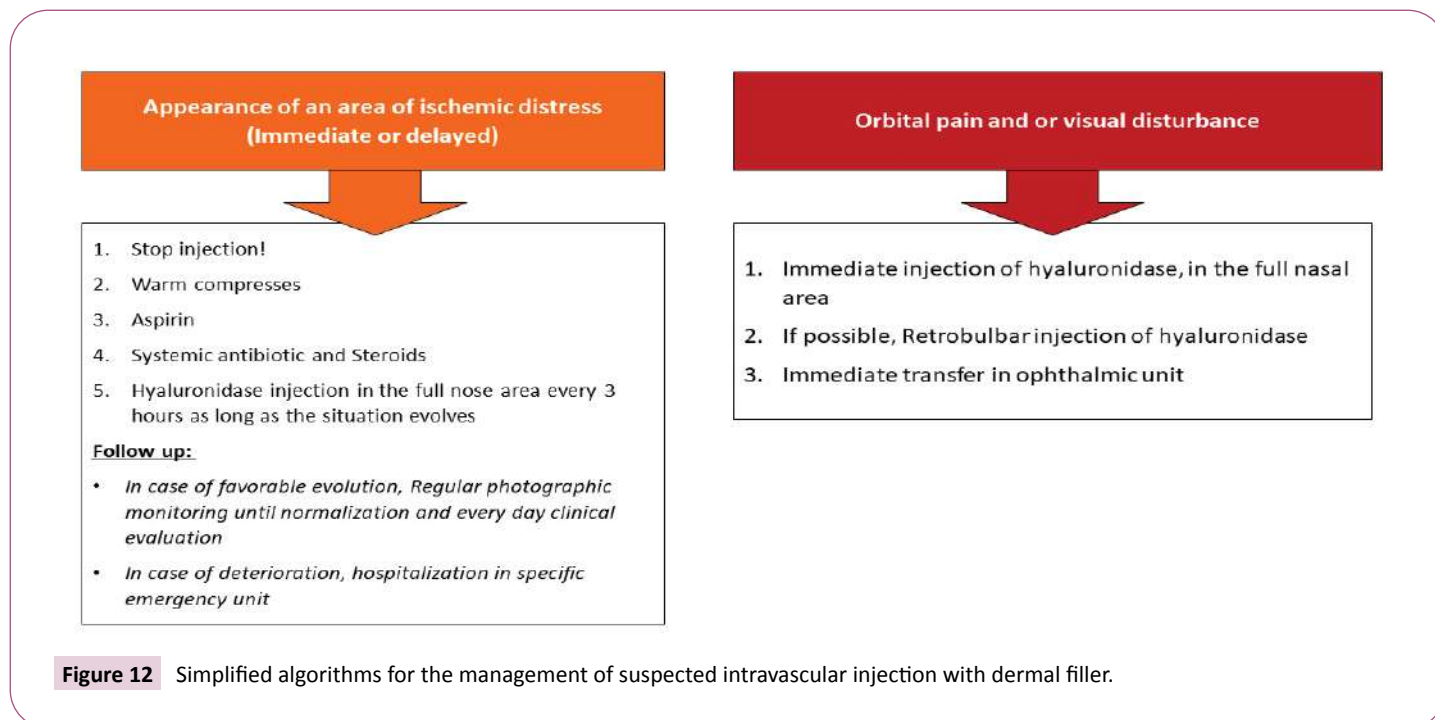
### Asia specificity

The Asian concept of beauty has changed over the years largely due to the influence of Western culture. Although there are

anatomic variations among different Asian populations, most Asians have thicker, oilier skin, more subcutaneous tissue and a lower dorsum than Caucasians [18]. Their nasal bones tend to be smaller in height and width compared with that of Caucasians. The Asian nasal tip is usually under-projected and lacking in definition due to abundant fibrofatty tissue, weaker lower lateral cartilages, and a short columella. The nasolabial angle tends to be acute due to a retracted columella and premaxillary hypoplasia. The alar lobules are thick, and the alar bases are usually wide. Finally, the radix in Asians usually is lower compared with that in Caucasians [1]. Due to these anatomical differences, it may be more difficult to perform MR on these patients who may experience severe post procedure edema more often and because creating a pleasing 3-dimensional shape is challenging. However, minute irregularities or asymmetry can be camouflaged more easily compared with patients with thin skin [18]. Although many Asian females seek a higher nose and definition with nasal dorsum augmentation and additional tip projection and angulation, they still want to preserve their ethnic identity by refining their Asian features rather than totally Westernizing their appearance [1]. In Asia silicone implants or alloplastic material are the most widely used nasal augmentation techniques [1]. However, these surgeries are constraining, make removal of the implant more difficult and are associated with complications. One large study involving silicone implants in Asian rhinoplasties revealed an 8% reoperation rate and a 16% complication rate including 5.3% of infection, 2.8% of extrusion, 5.0% of deviation, 2.8% of deformities [19]. Autogenous augmentation was also widely used but is limited due to the donor site morbidity, the limited donor material, the increased operative time, the uncertain graft resorption and susceptibility to warping and the prescription of oral antibiotics for up to a week following surgery [20]. Moreover, Asian patients undergoing surgical rhinoplasty are more prone to hyperpigmentation, hypertrophic or keloid scarring potentially from rib harvest, and prolonged edema than Caucasians [1]. Therefore, in this population, due to its flexibility, reversibility and its safety MR is more suitable than surgical rhinoplasty. Tansatit et al. performed a histological analysis of midline longitudinal sections of the Asian nose and showed that most nasal arteries found in the midline are subcutaneous arteries. The authors recommend to inject fillers deeply to avoid vascular injury leading to compromised perfusion at the dorsum or filler emboli at the nasal tip [21].

### Side effects

As stated by a group of expert, HA fillers have an extremely good safety profile compared with other types of fillers [4]. Autologous fat is more often associated with vascular complications and especially permanent blindness than HA [22]. Belezny et al. [23] Showed that autologous fat was responsible for 47.9% of cases of unilateral permanent blindness, followed by HA (23.5%), collagen (8.2%), poly-L-lactic acid (3.1%), and calcium hydroxylapatite (2%). However, these results should be considered taking into account the number of each procedure. Since HA is the most used filler in the world for this indication, this suggests that HA is actually less associated with vascular complications than other fillers. Moreover, since the publication, the techniques of



injection and products have improved. There were no reports of product migration, which contrasts with clinical experience with particle suspension gels. Side effects reported were slight risk of redness or bruising at the injection sites that quickly and naturally disappear. The smooth flow properties of the gel allow gentle, gradual injection of the product to the treatment area and facilitate precision of product placement [24]. A recent review reported 93 cases of vascular complications after facial filler injection [22] however; there is no available precise information about the precise number of the whole nose injection in order to be able to calculate the risk of this serious complication. Unilateral blindness is the most frequent vascular adverse event associated with cosmetic fillers for facial tissue augmentation [22]. Sito et al. described recently in a meta-analysis that, among the cases with either visual loss or blindness, a total or partial recovery was observed in 46% of the patients while 54% of the subjects didn't recover. This high proportion of irreversible blindness despite the use of hyaluronidase could be partially explained by the misuse of hyaluronidase. The authors underlined that the treatment with hyaluronidase was administered only in one patient on four which reduce the likelihood to recover. In addition, authors revealed an excessive time gap between symptoms onset and hyaluronidase injection, ranging from 3 to 24 hours, with five over seven cases exceeding the four-hour safety threshold. Serious vascular complications should not be confounded with painless visual complains such as tunnel vision or graying of vision associated with vasovagal reaction. Indeed, these benign adverse events are not infrequent and may be resolved by immediate interruption of the injection and putting the patient in supine position [25].

## Prevention

It is crucial for injecting physicians to have a detailed knowledge of the vascular anatomy and be prepared to serious adverse event management. Based on recommendations published by

experts and our experience, below are listed precautions for HA fillers injections [4,25]:

- ▶ withdraw make-up
- ▶ herpes prophylaxis if applicable
- ▶ temporarily treatment discontinuation (anticoagulant, immunomodulators) if applicable
- ▶ aspiration before injection
- ▶ slow injection with minimal pressure
- ▶ small volumes per pass
- ▶ bolus or linear and retracing injection
- ▶ keep the needle moving
- ▶ move tip with delivery of product
- ▶ Blunt cannula has been advocated as safer than sharp needles because it would be more difficult to perforate the arterial wall. The cannula is preferred for long dorsum filling with entrance point at the tip, while needle are preferred for precise correction and small deposits
- ▶ digitally pressing the skin against lateral walls with two fingers to avoid diffusion
- ▶ tip adjustment in final step
- ▶ stay in superficial plane to avoid complication in the glabella

## Treatment

Although visual loss frequently occur at the time of injection, it may take several hours or even days to be manifested by patients [23]. Therefore a short term follow-up is important.



The major advantage with HA is the availability of hyaluronidase, an efficient treatment which can completely reverse the effect of HA when injected into or around the occluded blood vessel. There are several available forms of hyaluronidase. Products that are manufactured without thiomersal and not compounded, as some patients are allergic to components of the material, are recommended [26].

The treatment of suspected intra-vascular injection of HA fillers rest on the immediate cessation of the injection, injection of hyaluronidase and massage with warm compresses, if appropriate. The **Figure 12** shows a simplified algorithm developed by a group of experts. In case of non-intravascular obstruction, the recommendation is a single injection of 10 to 20 U hyaluronidase for areas less than 2.5 mm and two to four injections of 10 to 20 U hyaluronidase for areas greater than 2.5 mm. Hyaluronidase should not be injected in case of infection unless the patient is already on antibiotic treatment or intravascular occlusion is suspected, in whom, hyaluronidase should be started immediately [4]. In case of intravascular occlusion, a minimum of 200 to 300 U of hyaluronidase should be injected spread over the entire area, where symptoms are present, and repeated daily (minimum of 2 days) until signs of permanent necrosis disappear or reestablished blood flow appear. A larger dose, 500 to 1500 U, should be used if needed to avoid tissue necrosis. The patient should be followed every day [4]. In case of retinal artery obstruction, it has also been suggested to use topical nitroglycerin paste 1% [4], retrobulbar injection of a large volume of hyaluronidase or massive systemic intravenous injection of hyaluronidase as is done for myocardial infarction [26].

## Conclusion

Now-a-days, medical rhinoplasty represents a safe and common aesthetic procedure especially in Asian population. However, a good knowledge of anatomy and the injection technique are

absolutely essential for this zone. MR represents an interesting first line treatment in patients that are not willing to have surgery, who have contra-indications for the surgery or for patients who do not seek permanent and radical solution. It is also useful as a complement for non-satisfactory surgical interventions. Thanks to the precision and the easy procedure, MR is a more artistic approach of rhinoplasties. In addition, it allows the involvement of the patient in order to better fit their expectations. In a society where the changes and the decision are faster and faster, MR allows a dramatic modification in few minutes and the recovery is faster than surgical rhinoplasties.

There is no standard measuring method for quantify the clinical results of injection in this zone. "Braccini index" by Newton® Technology is the first quantitative non-invasive and reliable method which could analyse all standard photos before and after the injection.

The selection of dermal filler with the relevant rheological properties is a key factor in achieving a natural-looking long-lasting desired aesthetic outcome. ART FILLER® Universal (Laboratoires FILLMED, France) showed a great safety and a significant efficacy to decrease the "Braccini Index" resulting in a decrease of the tortuosity of the nose bridge.

## Acknowledgments

Special thanks to Doctor Alexandre Guichard, for his precious help to prepare this article. The authors appreciate also Mrs Magali Murro, the assistant of "L'Artistique" Medical Healthcare Center, for her invaluable helps to providing the patient files and their photos.

## Funding Support

No funding support for this work.

## References

- 1 Ishii CH (2014) Current update in Asian Rhinoplasty. *Plast Reconstr Surg Glob Open* 2: e133.
- 2 Rettinger G (2007) Risks and complications in rhinoplasty. *GMS Curr Top Otorhinolaryngol Head Neck Surg*. 6: 8.
- 3 Liew S, Scamp T, De Maio M, Halstead M, Johnston N, et al. (2016) Efficacy and safety of a hyaluronic acid filler to correct aesthetically detracting or deficient features of the Asian nose: A prospective, open-label, long-term study. *Aesthet Surg J* 36: 760-772.
- 4 Signorini M, Liew S, Sundaram H, De Boule KL, Goodman GJ, et al. (2016) Global Aesthetics consensus: Avoidance and management of complications from hyaluronic acid fillers-evidence- and opinion-based review and consensus recommendations. *Plast Reconstr Surg* 137: 961e-971e.
- 5 Lee W, Yoon JH, Koh IS, Oh W, Kim KW, et al. (2018) Clinical application of a new hyaluronic acid filler based on its rheological properties and the anatomical site of injection. *Biomed Dermatol* 2: 22.
- 6 Pierre S, Liew S, Bernardin A (2015) Basics of dermal filler rheology. *Dermatol Surg Off Publ Am Soc Dermatol Surg Al* 41: 120-126.
- 7 Hee CK, Shumate GT, Narurkar V, Bernardin A, Messina DJ (2015) Rheological properties and in vivo performance characteristics of soft tissue fillers. *Dermatol Surg Off Publ Am Soc Dermatol Surg Al*. 41: S373-S381.
- 8 Trevidic P, Andre P, Benadiba L, Deutsch JJ, Galatoire O, et al. (2020) objective 18-month comparison of the tolerability of 2 dermal fillers formulated with tri-hyal technology. *Plast Reconstr Surg*.
- 9 Kalantar Motamedi MH, Ebrahimi A, Shams A, Nejad Sarvari N (2016) Health and social problems of rhinoplasty in Iran. *World J Plast Surg* 5: 75-76.
- 10 Hosseinzadeh K, Hamadzadeh H, Khorasani M, Jamshidi M (2017) Health related quality of life of persons after rhinoplasty: A longitudinal study among Iranian population. *J Clin Diagn Res* 11: 60-62.
- 11 Salehahmadi Z, Rafie SR (2012) Factors affecting patients undergoing cosmetic surgery in Bushehr, Southern Iran. *World J Plast Surg* 1: 99-106.
- 12 Gavard Molliard S, Bon Bétemps J, Hadjab B, Topchian D, Micheels P, et al. (2018) Key rheological properties of hyaluronic acid fillers: from tissue integration to product degradation. *Plast Aesthetic Res* 5: 17.

- 13 Braccini F, Dohan Ehrenfest DM. Medical rhinoplasty: Rationale for atraumatic nasal modelling using botulinum toxin and fillers. *Rev laryngol otol rhinol* 129: 1-6.
- 14 Sena Esteves S, Gonçalves Ferreira M, Carvalho Almeida J, Abrunhosa J, Almeida Sousa C (2017) Evaluation of aesthetic and functional outcomes in rhinoplasty surgery: A prospective study. *Braz J Otorhinolaryngol* 83: 552-557.
- 15 Grymer LF (1995) Reduction rhinoplasty and nasal patency: change in the cross-sectional area of the nose evaluated by acoustic rhinometry. *The Laryngoscope* 4: 429-431.
- 16 Huempfer-Hierl H, Hemprich A, Hierl T (2009) Results of a prospective anthropometric and functional study about aesthetics and nasal respiration after secondary rhinoplasty in cleft lip and palate patients. *J Craniofac Surg* 20: 1863-1875.
- 17 Hormozi AK, Toosi AB (2008) Rhinometry: an important clinical index for evaluation of the nose before and after rhinoplasty. *Aesthetic Plast Surg* 32: 286-293.
- 18 Moon HJ (2018) Injection Rhinoplasty Using Filler. *Facial Plast Surg Clin N Am* 26: 323-330.
- 19 Tham C, Lai YL, Weng CJ, Chen YR (2005) Silicone augmentation rhinoplasty in an Oriental population. *Ann Plast Surg* 54: 1-5.
- 20 Karnes J, Salisbury M, Schaeferle M, Beckham P, Ersek RA (2000) Porous high-density polyethylene implants (Medpor) for nasal dorsum augmentation. *Aesthet Surg J* 20: 26-30.
- 21 Tansatit T, Moon HJ, Rungsawang C, Jitree B, Uruwan S, et al. (2016) Safe planes for injection rhinoplasty: a histological analysis of midline longitudinal sections of the asian nose. *Aesthetic Plast Surg* 40: 236-244.
- 22 Sito G, Manzoni V, Sommariva R (2019) Vascular complications after facial filler injection: a literature review and meta-analysis. *J Clin Aesthet Dermatol* 12: E65-E72.
- 23 Beleznyay K, Carruthers JDA, Humphrey S, Jones D (2015) Avoiding and treating blindness from fillers: a review of the world literature. *Dermatol Surg Off Publ Am Soc Dermatol Surg Al* 41: 1097-1117.
- 24 Alessandrini A, Fino P, Giordan N, Amorosi V, Scuderi N (2015) Evaluation of a new hyaluronic acid dermal filler for volume restoration. *J Cosmet Laser Ther Publ Eur Soc Laser Dermatol* 17: 335-342.
- 25 Lacerda D (2018) Prevention and management of iatrogenic blindness associated with aesthetic filler injections. *Dermatol Ther* 31: e12722.
- 26 Carruthers JDA, Fagien S, Rohrich RJ, Weinkle S, Carruthers A (2014) Blindness caused by cosmetic filler injection: A review of cause and therapy. *Plast Reconstr Surg* 134: 1197-1201.